Orthopaedics & Traumatology: Surgery & Research 100 (2014) 891–894

Available online at
ScienceDirect
www.sciencedirect.com

Elsevier Masson France
EM|consulte
www.em-consulte.com/en

Original article

Vascular injuries during closing-wedge high tibial osteotomy: A cadaveric angiographic study

A. Darnis[a,b,*], V. Villa[a], C. Debette[a], S. Lustig[a], E. Servien[a], P. Neyret[a]

[a] Service de chirurgie orthopédique, centre Albert-Trillat, université Claude-Bernard Lyon 1, hôpital de la Croix-Rousse, hospices civils de Lyon, 103, Grande-Rue-de-la-Croix-Rousse, 69004 Lyon, France
[b] Laboratoire d'anatomie, faculté de médecine Rockefeller, université Claude-Bernard Lyon 1, 8, avenue Rockefeller, 69003 Lyon, France

ARTICLE INFO

Article history:
Accepted 30 July 2014

Keywords:
Anatomical study
High tibial osteotomy
Closing-wedge
Vascular injury
Popliteal artery

ABSTRACT

Introduction: Closing-wedge high tibial osteotomy is a surgical option for patients with isolated medial compartment osteoarthritis and varus knee alignment. Vascular complications are rare, but incriminate the use of oscillating saw or osteotome. It is important to know the steps of this surgery that involve risk of vascular injury and what to do to decrease that risk.
Hypothesis: Performing the distal osteotomy cut using an oscillating saw is a step with high risk of vascular injury. A protective device behind the tibia may decrease this risk.
Materials and methods: In this descriptive angiographic cadaver study, closing-wedge high tibial osteotomy was performed on 6 cadaveric knees in 90° knee flexion, and the distance between the surgical instrument and the popliteal artery was measured on fluoroscopy with artery opacification at the various steps of surgery.
Results: Tibial osteotomy with oscillating saw involves high vascular risk: the mean distance between the saw-blade and the popliteal artery is 10.6 mm in 90° knee flexion. Using a specific device placed behind the tibia protects the vascular structures.
Discussion: High tibial osteotomy is indicated in medial compartment osteoarthritis of the knee and can be performed by closing or opening-wedge. Vascular injuries in closing-wedge osteotomy exist and it is recommended to perform this surgery at 90° knee flexion, although some studies report that this does not move the artery out of the way. A risk of vascular lesion should be kept in mind. The oscillation of the saw and the direction of the osteotomy should also be taken into consideration when performing a closing-wedge high tibial osteotomy in order to protect the popliteal artery.
Study design: Descriptive cadaver study. Level IV.

1. Introduction

High tibial osteotomy (HTO) is a surgical option in isolated medial compartment osteoarthritis with varus knee. The procedure is not free of possible complications, and the risk of lesion to the nearby popliteal artery ranges in the literature between 0.4% and 9.8% [1,2]. The steps in the procedure that involve such risk need to be known, as do the anatomic variants liable to increase it. Following a case of popliteal artery branch lesion sustained during closing-wedge HTO, an angiographic cadaver study was performed to identify the risks in the procedure by measuring the distance between instruments and artery during the various steps. The study hypothesis was that performing the distal osteotomy cut using an oscillating saw is a step with high risk of vascular injury and that a protective device behind the tibia may decrease this risk.

2. Material and method

The study was performed on 6 lower limbs from 3 whole fresh cadavers: 3 right and 3 left knees (Anatomy Laboratory, Rockefeller Medical Faculty, Claude-Bernard University, Lyon, France). The cadavers were stored at 4 °C and exposed to room temperature (18 °C) for 12 hours before examination. Specimens with scarred skin over the knee were excluded, and AP and lateral fluoroscopy ruled out any obvious abnormality (trauma, tumor, material). The cadavers were positioned in dorsal decubitus, with a support holding the knee in 90° flexion. The fluoroscope was positioned so as to obtain the lateral view. The femoral artery was approached via the

* Corresponding author. Service de chirurgie orthopédique, centre Albert-Trillat, université Claude-Bernard Lyon 1, hôpital de la Croix-Rousse, hospices civils de Lyon, 103, Grande-Rue-de-la-Croix-Rousse, 69004 Lyon, France. Tel.: +33 6 76 82 45 29.
E-mail addresses: alice.darnis@icloud.com, alice.darnis@chu-lyon.fr (A. Darnis).

http://dx.doi.org/10.1016/j.otsr.2014.07.021
1877-0568/

femoral triangle with the limb in extension, and a 16-gauge latex probe was introduced into the artery and held in place by suture. The posterior tibial artery was identified behind the medial malleolus and an opening allowed the substance injected into the femoral artery to be evacuated. Physiological saline was then injected via a femoral catheter to remove any clots and to check permeability. The arterial opacifier used was Telebrix (Guerbet, France) in a 50% physiological saline solution. The various steps of closing-wedge HTO were performed following the procedure adopted in the authors' surgery department [3].

2.1. Closing-wedge high tibial osteotomy technique

The entire procedure was performed with the knee in 90° flexion. The skin incision was oblique, on the anterolateral side of the tibia, 1 cm above the anterior tibial tuberosity and 1 cm under the fibular head. The anterior tibial aponeurosis was opened, conserving a small superior "skirt", and the anterior tibial and extensor digitorum muscles were released downward by raspatory. Fibular neck osteotomy was performed with 4 holes drilled in the neck with a 3.2-mm bit then cutting with a Lambotte osteotome. Tibial osteotomy used dedicated instrumentation (Tornier HTO, Saint Ismier, France). A K-wire was placed in the joint line, then a guide-wire 1 cm below, via the instrumentation. A bone chisel was slid along the wire, stopping 1 cm short of the medial cortex. A drill guide was then impacted and slid along the wire, and holes were drilled with a 6-mm bit. The blade plate was slid along the wire and impacted until the head was embedded in the bone. The inferior osteotomy line was cut using an oscillating saw, respecting the anterior tibial tuberosity and superior tibiofibular joint. A raspatory was then placed behind the tibia, to protect the popliteal artery (Fig. 1). The raspatory was introduced laterally, in direct contact with the tibia, under the periosteum and forward of the soleus, lateral gastrocnemius and popliteal muscles. The superior section was cut by oscillating saw using an 8° guide and the bone wedge was withdrawn. A temporary screw was introduced in the distal fragment 1 cm from the osteotomy line, and reduction was maintained by forceps supported by the screw and by the head of the plate, allowing two definitive bicortical screws to be introduced through the plate.

A fluoroscopic lateral view of the knee, defined by superposition of the lateral and medial condyles, was taken after contrast medium injection through the femoral catheter during the plate impaction and tibial osteotomy by oscillating saw. On each image, the scale was given by a 2-mm diameter wire in the tibia or femur. Four measurements were taken:

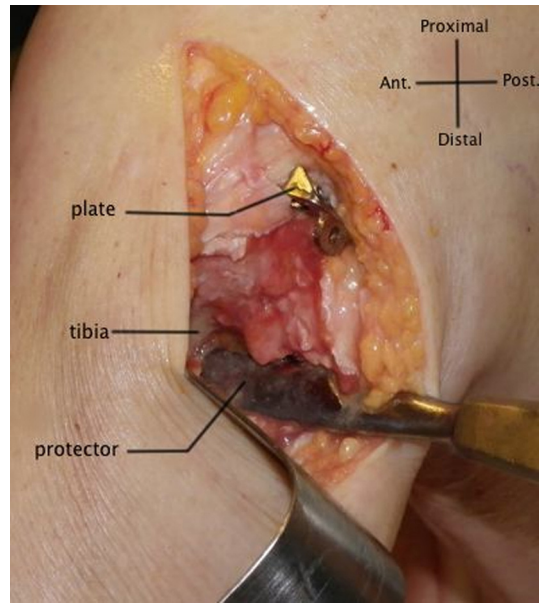

Fig. 1. Left knee tibial osteotomy. Raspatory positioned behind tibia to protect the popliteal artery.

- distance between the popliteal artery and the posterior tibial cortex 2 cm under the joint line;
- distance between the artery and the posterior edge of the plate;
- distance between the artery and the saw-blade (with the blade in stop position);
- distance between the artery and the raspatory at the time of tibial osteotomy (Fig. 2).

The study was repeated on all 6 limbs, and all measurements were taken on fluoroscopic images.

3. Results

All specimens showed a classical arrangement of the popliteal vessels. Results are presented in Table 1. The popliteal artery was 2 cm under the joint line, at a mean 11.7 mm (range, 10.2–12.8) from the posterior tibial cortex, in 90° flexion. When the blade plate was introduced, some 10 mm under the joint line, the mean distance between its posterior edge and the artery was 24.7 mm (20.1–28.1). During distal osteotomy by oscillating saw, some 30 mm under the joint line, the saw-blade was a mean 10.6 mm (7.5–11.8) from the artery, with the knee in 90° flexion. The

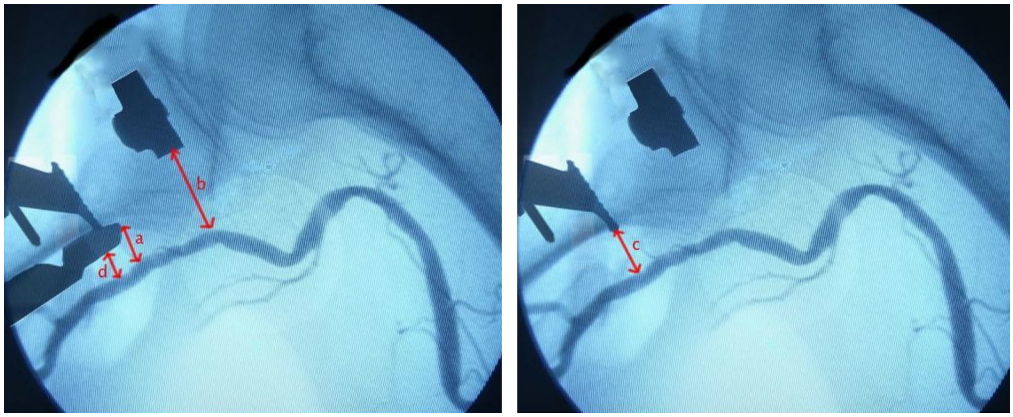

Fig. 2. Measurements on fluoroscopic view: distance between popliteal artery and (a) posterior tibial cortex, (b) blade-plate, (c) oscillating saw and (d) raspatory. 2-mm diameter tibial wire for calibration.

Table 1
Distances of fluoroscopic views.

Distance (mm)	Knee 1	Knee 2	Knee 3	Knee 4	Knee 5	Knee 6
Between popliteal artery and posterior tibial cortex	11.9	10.2	12.2	11.4	11.9	12.8
Between popliteal artery and blade-plate	27.8	22.3	22.8	28.1	20.1	26.9
Between popliteal artery and saw	11.8	9.5	11.4	7.5	11.7	11.5
Between popliteal artery and protective device	7.9	6.6	7.5	5.2	8.9	9.5

raspatory (width, 13 mm) behind the posterior tibial cortex protected the vessels during the sawing of the tibia; the mean distance between the raspatory and the artery was 7.6 mm (5.2–9.5).

4. Discussion

High tibial osteotomy is indicated for medial compartment osteoarthritis with varus knee. There are, schematically, two types of procedure: opening- and closing-wedge HTO. Opening-wedge HTO does not involve fibular osteotomy, avoiding the risks of fibular non-union and peroneal nerve lesion [4,5], but may be complicated by problems of tibial fusion. Closing-wedge HTO shows better fusion and tends to reduce tibial slope, but with greater risk for the peroneal nerve. Song et al. [6] compared risk between the two and found no significant difference in major complications. They did, however, report two cases of compartment syndrome with closing-wedge HTO, which can be difficult to differentiate from vascular or neural lesion: vascular lesions can induce lower limb compartment syndrome, which may in turn induce neural lesions [7]. Efe et al. [2], in 199 closing-wedge HTOs, reported a 19% complications rate, including 9 vascular complications: 8 deep venous thromboses and 1 arterial lesion. Vascular lesions have also been reported in opening-wedge HTO [8,9], and more rarely in closing-wedge HTO [7,10]. The most frequent vasculo-neural complication in closing-wedge HTO is peroneal palsy, with incidence of 0–20% in the literature [11]. Georgoulis et al. [7] reported 1 case of popliteal artery lesion with an oscillating saw, and Zaidi et al. [10] reported 1 case of arterial lesion by osteotome. Anterior tibial artery lesions are more frequent, principally due to the type IIA anatomic variant on the Kim classification [12], in which the artery is in direct contact with the posterior tibial cortex and may be damaged by the saw during osteotomy or by the retractors. In the present study, no specimens showed vascular variants. Sawant and Ireland [13] described a case of pseudo-aneurysm in a recurrent branch of the anterior tibial artery.

To minimize such risks, it is classically recommended to position the retractors in contact with the bone, to protect the vessels, and to perform osteotomy with the knee in 90° flexion. Several studies have described the movement of the popliteal artery under knee flexion and most reported that it moved away from the posterior tibial cortex [14–16]. This is why we performed our study with knees in 90° flexion, to demonstrate the vulnerability of the popliteal vessels during osteotomy despite this protective maneuver. The basic claim, however, is debatable: flexion may distance the popliteal artery from the posterior femoral cortex, but the same can probably not be said of the tibia due to the limited movement of the vessels through the soleus tendinous arch. Zaidi et al. [10] reported approximation of the popliteal artery to the tibia 1.5 cm under the joint line in 12 cases out of 20 in flexion; these findings are subject to criticism, as subjects were in lateral decubitus during measurement, eliminating the gravitational effect on the vessels. Smith et al. [17], in an MRI study performed with subjects in dorsal decubitus, reported approximation of the popliteal artery to the posterior tibial cortex at the level of the osteotomy under knee flexion in 2 cases out of 9. In the present study, the mean distance between the tibia and the artery at the osteotomy was 11.7 mm, in 90° knee flexion. One study limitation is the lack of measurement in extension, for comparison. In a study with a methodology similar to the present, Kim et al. systematically found increased distance between the popliteal artery and the posterior tibial cortex under flexion, 5 and 20 mm under the joint line [18]. Flexion also reduced popliteal artery tension, thus decreasing the risk of surgical lesion [16,19]. We think high tibial osteotomy should indeed be performed with the knee in flexion, but keeping in mind that the vessels remain vulnerable.

It should be noted that the distance between blade and artery was measured with the saw immobile, without allowing for blade oscillation. In its stop position, the saw-blade is in an intermediate



Fig. 3. Distances according to saw-blade oscillation: (a) immobile; (b) shortest distance under operating conditions. E.g., for a 50 × 20 mm blade with 5° oscillation angle, a ≈ b + 4 mm

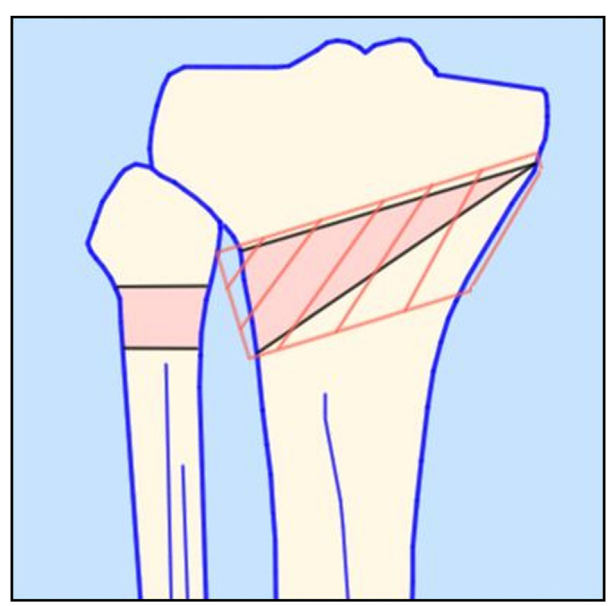

Fig. 4. Area requiring protection by a device of suitable width during osteotomy.

position, leading to overestimation of the distance from the artery. Approximation under operating conditions is particularly great when oscillation is maximal at the end of the blade, nearest to the artery during osteotomy. In the present study, the blade measured 50×20 mm with an oscillation angle of 5°, so that the distance was overestimated by not more than 4 mm (Fig. 3). Kim et al. [18] studied the risk of vascular lesion according to the angle between the saw-blade and the frontal plane: risk increased when the angle exceeded 30°, despite the posterior presence of the popliteal muscle.

It is important to place a device in direct contact with the tibia, to protect the vessels from the saw or osteotome; the device, a flexible metal blade or a raspatory, should be wide enough to cover the whole cut, taking account both of the width of the saw-blade (generally 0.6 to 1.2 mm) and the line of the cut, going obliquely inward and upward. A more specific device may be needed, with a width sufficient for a single positioning behind the tibia to cover the entire height over which the blade could endanger the popliteal artery (Fig. 4).

5. Conclusion

Closing-wedge high tibial osteotomy is a classical procedure in medial compartment osteoarthritis, but is not without risk for the popliteal vasculo-neural structures. The distal osteotomy performed using an oscillating saw is a step involving high risk of vascular lesion and should be undertaken with caution, the knee in 90° flexion, with a protective device placed in direct contact with the posterior tibial cortex. The anatomy of the popliteal artery and its branches needs to be known, as do the anatomic variants liable to increase the risk involved in knee surgery.

Disclosure of interest

P. Neyret receives royalties from Tornier, but with no direct conflict of interest for this article (the HTO plate no longer being marketed).

Acknowledgments

B. Darnis, H. Daudet and C. Vouyovitch for operative help, and the Anatomy laboratory of the East Lyon Medical faculty (Pr P. Mertens) for providing material.

References

[1] Atrey A, Morison Z, Tosounidis T, Tunggal J, Waddell JP. Complications of closing wedge high tibial osteotomies for unicompartmental osteoarthritis of the knee. Bone Joint Res 2012;1:205–9.
[2] Efe T, Ahmed G, Heyse TJ, Boudriot U, Timmesfeld N, Fuchs-Winkelmann S, et al. Closing-wedge high tibial osteotomy: survival and risk factor analysis at long-term follow up. BMC Musculoskeletal Disorders 2011;12:46.
[3] Neyret P, Demey G. Traité de chirurgie du genou. Elsevier Masson; 2012.
[4] Spahn G, Wittig R. Primary stability of various implants in tibial opening wedge osteotomy: a biomechanical study. J Orthop Sci 2002;7:683–7.
[5] Dowd GSE, Somayaji HS, Uthukuri M. High tibial osteotomy for medial compartment osteoarthritis. Knee 2006;13:87–92.
[6] Song EK, Seon JK, Park SJ, Jeong MS. The complications of high tibial osteotomy: closing- versus opening-wedge methods. J Bone Joint Surg Br 2010;92:1245–52.
[7] Georgoulis AD, Makris CA, Papageorgiou CD, Moebius UG, Xenakis T, Soucacos PN. Nerve and vessel injuries during high tibial osteotomy combined with distal fibular osteotomy: a clinically relevant anatomic study. Knee Surg Sports Traumatol Arthrosc 1999;7:15–9.
[8] Szyber P, Skóra J, Rybak W, Pupka A. Iatrogenic pseudoaneurysm of the popliteal artery following corrective tibial osteotomy. VASA 2011;40:414–7.
[9] Shenoy PM, Oh HK, Choi JY, Yoo SH, Han SB, Yoon JR, et al. Pseudoaneurysm of the popliteal artery complicating medial opening wedge high tibial osteotomy. Orthopedics 2009;32:442.
[10] Zaidi SH, Cobb AG, Bentley G. Danger to the popliteal artery in high tibial osteotomy. J Bone Joint Surg Br 1995;77:384–6.
[11] Tunggal JAW, Higgins GA, Waddell JP. Complications of closing wedge high tibial osteotomy. Int Orthopaedics 2009;34:255–61.
[12] Kim D, Orron DE, Skillman JJ. Surgical significance of popliteal arterial variants. A unified angiographic classification. Ann Surg 1989;210:776–81.
[13] Sawant MR, Ireland J. Pseudo-aneurysm of the anterior tibial artery complicating high tibial osteotomy – a case report. Knee 2001;8:247–8.
[14] Shetty AA, Tindall AJ, Qureshi F, Divekar M, Fernando KWK. The effect of knee flexion on the popliteal artery and its surgical significance. J Bone Joint Surg 2003;85:218–22.
[15] Smith PN, Gelinas J, Kennedy K, Thain L, Rorabeck CH, Bourne RB. Popliteal vessels in knee surgery. A magnetic resonance imaging study. Clin Orthop Rel Res 1999:158–64.
[16] Vernon P, Delattre JF, Johnson EJ, Palot JP, Clément C. Dynamic modifications of the popliteal arterial axis in the sagittal plane during flexion of the knee. Surg Radiol Anat 1987;9:37–41.
[17] Smith JS, Shaffrey CI, Ames CP, Demakakos J, Fu K-MG, Keshavarzi S, et al. Assessment of symptomatic rod fracture after posterior instrumented fusion for adult spinal deformity. Neurosurgery 2012;71:862–7.
[18] Kim J, Allaire R, Harner CD. Vascular safety during high tibial osteotomy: a cadaveric angiographic study. Am J Sports Med 2010;38(4):810–5.
[19] Avisse C, Marcus C, Ouedraogo T, Delattre JF, Menanteau B, Flament JB. Anatomo-radiological study of the popliteal artery during knee flexion. Surg Radiol Anat 1995;17:255–62.